Diagnostic pitfalls in patients referred for arrhythmogenic right ventricular cardiomyopathy

James R. Sampognaro, MD, Sean P. Gaine, MB BCh, BAO, Apurva Sharma, MD, Crystal Tichnell, MGC, RN, Brittney Murray, CGC, Zeba Shaik, MSc, Stefan L. Zimmerman, MD, Cynthia A. James, PhD, Alessio Gasperetti, MD, PhD,[1] Hugh Calkins, MD, FHRS[1]

From the Division of Cardiology, Department of Medicine, The Johns Hopkins University School of Medicine, Baltimore, Maryland.

BACKGROUND The diagnosis of arrhythmogenic right ventricular cardiomyopathy (ARVC) is challenging because of nonspecific clinical findings and lack of conclusive answers from genetic testing (ie, an ARVC-related variant is neither necessary nor sufficient for diagnosis). Despite the revised 2010 Task Force Criteria, patients are still misdiagnosed with ARVC.

OBJECTIVE In patients referred for ARVC, we sought to identify the clinical characteristics and diagnostic confounders for those patients in whom ARVC was ultimately ruled out.

METHODS Patients who were referred to our center with previously diagnosed or suspected ARVC (between January 2011 and September 2019; N = 726) were included in this analysis.

RESULTS Among 726 patients, ARVC was ruled out in 365 (50.3%). The most common presenting symptoms in ruled-out patients were palpitations (n = 139, 38.1%), ventricular arrhythmias (n = 62, 17.0%), and chest pain (n = 53, 14.5%). On the basis of outside evaluation, 23.8% of these patients had received implantable cardioverter-defibrillators (ICDs) and device extraction was recommended in 9.0% after reevaluation. An additional 5.5% had received ICD recommendations, all of which were reversed on reevaluation. The most frequent final diagnoses were idiopathic premature ventricular contractions/ventricular tachycardia/ventricular fibrillation (46.6%), absence of disease (19.2%), and noncardiac presyncope/syncope (17.5%). The most common contributor to diagnostic error was cardiac magnetic resonance imaging, including mistaken right ventricular wall motion abnormalities (33.2%) and nonspecific fat (12.1%).

CONCLUSION False suspicion or misdiagnosis was found in the majority of patients referred for ARVC, resulting in inappropriate ICD implantation or recommendation in 14.5% of these patients. Misdiagnosis or false suspicion was most commonly due to misinterpretation of cardiac magnetic resonance imaging.

KEYWORDS Arrhythmogenic right ventricular cardiomyopathy; Cardiac magnetic resonance imaging; Implantable cardioverter-defibrillator; Misdiagnosis; Task Force Criteria

(Heart Rhythm 2023;20:1720–1726) © 2023 Heart Rhythm Society. All rights reserved.

Introduction

Arrhythmogenic right ventricular cardiomyopathy (ARVC) is difficult to diagnose. Patients with ARVC may present with dramatically different phenotypes, from cardiac arrest to largely asymptomatic at family screening.[1] Additionally, many hallmark features of ARVC, such as myocardial fibrosis, arrhythmogenesis, and sudden cardiac death, are observed in other types of cardiomyopathy.[2] Genetic testing likewise does not provide a straightforward diagnosis of ARVC, despite many pathogenic variants associated with the disease (often resulting in desmosomal protein abnormalities).[3] Around 40% of patients with ARVC do not carry a known causative variant, and a similar percentage of patients with a known pathogenic variant do not develop the disease.[4–6] Given the challenging nature of ARVC diagnosis, standardized diagnostic criteria were first developed by an international task force led by Dr Bill McKenna in 1994, later revised in 2010 in an attempt to improve diagnostic sensitivity.[7,8] Despite these criteria, however, patients are often misdiagnosed with ARVC, which can lead to ineffective treatments, inappropriate implantable cardioverter-defibrillator (ICD) implantation, unnecessary exercise restriction, and undue psychological distress for patients and their families.[9–11]

The Johns Hopkins ARVD/C program was established in 1999 to provide clinical care for patients with ARVC and to advance research into the disease. With this history and experience, our program has become a high-volume referral center for patients with ARVC. In this study, we examine the clinical characteristics of patients who were referred to our

[1]Drs Gasperetti and Calkins share senior coauthorship. **Address reprint requests and correspondence:** Dr Alessio Gasperetti, Division of Cardiology, Department of Medicine, The Johns Hopkins University School of Medicine, 600 N Wolfe St, Baltimore, MD 21287. E-mail address: alessio.gasperetti93@gmail.com.

1547-5271/$-see front matter © 2023 Heart Rhythm Society. All rights reserved. https://doi.org/10.1016/j.hrthm.2023.08.035

program with suspected or diagnosed ARVC, with a focus on those who were ultimately determined not to have the disease upon reevaluation by our center.

Methods

Study population

Figure 1 depicts how patients were selected for this study. All patients included in this study had previously suspected or diagnosed ARVC and underwent second opinion evaluation at the Johns Hopkins ARVC/D Center between January 2011 and September 2019 (N = 751). Patients were excluded from this study if they presented to our center as their first evaluation for the condition or if they were not initially referred for ARVC. Additionally, patients were excluded from the study if they were self-referred for second opinion on ARVC without a previous suspicion or diagnosis of ARVC by another center. Of the 751 patients who met these inclusion criteria, 25 were excluded from further analysis because their diagnosis remained unclear after reevaluation (ie, nonspecific "arrhythmogenic cardiomyopathy," "borderline ARVC," or no final diagnosis with ARVC remaining in the differential), leaving 726 patients with either confirmed definite or ruled-out ARVC.

Data collection

The Johns Hopkins Medicine Institutional Review Board approved this study, which was conducted in accordance with the Helsinki Declaration. Patient consent was obtained as part of our ARVC registry protocol. Patient characteristics and medical history were abstracted from a comprehensive manual chart review in the electronic health record. In accordance with our institutional practice, pre-referral clinical records of all patients were obtained and reviewed before each visit by a dedicated study member who was blinded to the final patient diagnosis. Reevaluation at our center consisted of an office visit with an expert cardiologist and genetic counselor who obtained a detailed family history and interpreted genetic test results when applicable. At reevaluation, a second opinion on previous testing was typically performed, and new tests were also obtained when appropriate. Such tests include genetic testing, electrocardiogram (ECG), transthoracic echocardiogram, cardiac magnetic resonance (CMR) imaging, and cardiac Holter/Zio patch monitors (iRhythm, San Francisco, CA). Second opinion was given by a dedicated team: Dr Hugh Calkins for ECG and Holter, Dr Stefan L. Zimmerman for CMR, and Ms Brittney Murray and Dr Cynthia A. James for genetic testing. For genetic testing, the American College of Medical Genetics and Genomics and the Association for Molecular Pathology consensus definition for variants was used.[12]

2010 Task Force Criteria and final diagnosis

Using these data, all patients were scored according to the 2010 Task Force Criteria (TFC) after reevaluation at our center. This scoring system is composed of major and minor criteria divided into 6 categories: (1) global or regional dysfunction and structural alterations, (2) tissue characterization of wall, (3) repolarization abnormalities, (4) depolarization/conduction abnormalities, (5) arrhythmias, and (6) family history.[8] Patients fulfill diagnostic criteria for ARVC if they meet 2 major criteria, or 1 major plus 2 minor criteria, or 4 minor criteria from different categories. The ultimate diagnosis, however, was confirmed using the clinical expertise of the evaluating cardiologists at our center. For

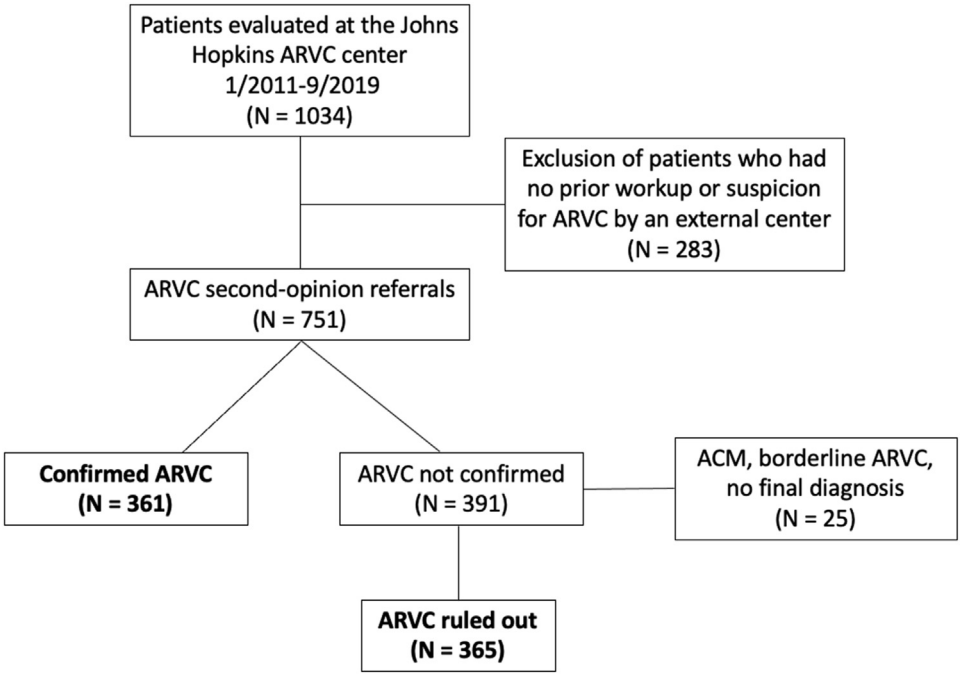

Figure 1 Flowchart for inclusion of the study population. ACM = arrhythmogenic cardiomyopathy; ARVC = arrhythmogenic right ventricular cardiomyopathy.

patients determined to not have ARVC, an alternative diagnosis was provided. CMR confounders were determined on the basis of the second opinion imaging reports and/or electrophysiology clinical notes. A "pericardial tether" refers to an apparent focal tethering of the anterior aspect of the right ventricular (RV) outflow tract and upper RV free wall in the midline that often results in a triangular appearance to the RV outflow tract and that has been seen by our group as a source of misdiagnosis of RV wall motion abnormalities (WMAs). Patients were considered to have a "true misdiagnosis" if they carried an initial diagnosis of ARVC that was reversed by our center, while they were considered to have a "false suspicion" if they had never been officially diagnosed (only suspected to have ARVC) before ARVC was ruled out by our evaluation.

Statistical analysis

Continuous variables are expressed as mean ± SD. Categorical variables are reported as number (percentage). Interrater reliability between external assessments and assessments by our high-volume center on various tests were determined using Cohen's κ, calculated using Microsoft Excel version 16.72 (Microsoft, Redmond, WA). Interrater agreement was graded as follows: 0 = none; 0.01–0.20 = slight; 0.21–0.40 = fair; 0.41–0.60 = moderate; 0.61–0.80 = substantial; 0.81–0.99 = near perfect; 1 = perfect.

Results

Final diagnosis

As depicted in Figure 1, our study included 726 patients who presented to our center with suspected or diagnosed ARVC, which was then confirmed or ruled out. ARVC was ultimately ruled out in 365 of these patients (50.3%), as shown in Table 1. True misdiagnosis had occurred in 86 patients (11.8%), while false suspicion had occurred in 279 patients (38.4%). The focus of this study was to analyze the characteristics of these 365 patients who presented with suspected or diagnosed ARVC but were determined by our center to not have the disease.

The baseline characteristics of these ruled-out patients are listed in Table 2. The mean age at the time of reevaluation was 41.0 years, and the majority were white (84.7%) and male (66.3%). The most common reasons for initial evaluation by the outside institutions were palpitations (38.1%), ventricular arrhythmia (17.0%), and chest pain (14.5%). Of the 365 patients, 87 (23.8%) had ICDs implanted on the basis of their outside evaluation; however, device extraction was recommended in 33 patients (9.0%) after their ICD was deemed inappropriate on reevaluation. An additional 20 ruled-out patients (5.5%) had been recommended or scheduled to have an ICD implanted, but these recommendations were reversed after second opinion evaluation. Of the 54 patients whose ICDs were deemed appropriate (eg, patients with cardiac sarcoidosis), 16 (4.4% of 365 patients) received appropriate shocks only, 1 (0.3%) experienced inappropriate shocks only, and 2 (0.5%) received both appropriate and inappropriate shocks. In addition to inappropriate shocks, other ICD-associated complications occurred for 2 patients (0.5%) with appropriate ICDs, including device infection (1 patient) and lead failure requiring revision (1). Of the 33 patients with inappropriate ICDs, 9 (2.5%) experienced inappropriate shocks and none received appropriate shocks. Other ICD-associated complications occurred for 9 patients with inappropriate ICDs (2.5%) (some patients with multiple complications), including device infection (4), lead failure requiring revision (3), deep vein thrombosis (2),

Table 1 Diagnostic accuracy of referrals to our center

Variable	ARVC confirmed	ARVC ruled out	Total
Diagnosed pre-referral	198	86	284
Suspected pre-referral	163	279	442
Total	361	365	726

ARVC = arrhythmogenic right ventricular cardiomyopathy.

Table 2 Clinical characteristics of ruled-out patients (N = 365)

Characteristic	Value
Patient characteristic	
Age at evaluation (y)	41.0 ± 15.9
Male sex	242 (66.3)
Race	
White	309 (84.7)
Other/unknown	24 (6.6)
Black	20 (5.5)
Asian	11 (3.0)
American Indian	1 (0.3)
Hispanic/Latino	1 (0.3)
Native Hawaiian/Pacific Islander	1 (0.3)
Reason for outside presentation	
Palpitations	139 (38.1)
Ventricular arrhythmia	62 (17.0)
Chest pain	53 (14.5)
Asymptomatic, incidental finding	36 (9.9)
Asymptomatic, family history SCD	36 (9.9)
ICD history	
Patients with appropriate ICDs	54 (14.8)
Appropriate shocks only	16 (4.4)
Inappropriate shocks only	1 (0.3)
Mixed shocks	2 (0.5)
Other ICD-related adverse event*	2 (0.5)
Patients with inappropriate ICDs	33 (9.0)
Appropriate shocks only	0 (0.0)
Inappropriate shocks only	9 (2.5)
Mixed shocks	0 (0.0)
Other ICD-related adverse event†	9 (2.5)
ICD recommended only at the initial evaluation	20 (5.5)
Recommendation contradicted at reevaluation	20 (5.5)

Values are presented as mean ± SD or n (%).

ICD = implantable cardioverter-defibrillator; SCD = sudden cardiac death.

*Device infection (1) and lead failure (1).

†Some patients had device infection (4), lead failure (3), deep vein thrombosis (2), vascular/cardiac avulsion requiring sternotomy (2), tamponade (1), pocket hematoma (1), and need for pocket revision (1).

periprocedural vascular tear/cardiac avulsion requiring sternotomy (2), periprocedural tamponade requiring pericardiocentesis (1), pocket hematoma (1), and hypermobile generator requiring pocket revision (1).

The final diagnoses given to the ruled-out patients are detailed in Figure 2. Note that some patients were given multiple diagnoses (eg, noncardiac syncope and idiopathic premature ventricular contractions [PVCs]). The most common diagnosis in these patients was idiopathic PVCs/ventricular tachycardia (VT)/ventricular fibrillation (VF), which was the case for 170 patients (46.6%). The second most common diagnosis was the absence of any abnormality, which was the case for 70 patients (19.2%). The third most common diagnosis was noncardiac presyncope or syncope, which applied to 64 of the ruled-out patients (17.5%). Notably, 4 ruled-out patients (1.1%) actually met 2010 TFC for the diagnosis of ARVC (ie, score ≥4), all of whom were ultimately diagnosed with cardiac sarcoidosis.

Diagnostic pitfalls

Certain patterns of diagnostic pitfalls revealed themselves in patients who were determined not to have ARVC upon second opinion evaluation. The most common contributors are listed in Table 3. False-positive interpretations of RV WMAs on CMR were the most frequent errors, having occurred in 121 patients (33.2%). In 59 of these patients, there was a clear confounder that led to the misinterpreted WMA, including pericardial tether (7.1% of the ruled-out patients), pectus excavatum (5.8%), or arrhythmia/conduction artifact (3.3%). Representative examples of pericardial tether and pectus excavatum are shown in Figures 3A–3E. Although not a part of the 2010 TFC, the findings of fat (12.1%) and RV wall thinning (3.6%) on CMR were also common contributors to misdiagnosis or false suspicion. Figures 3F–3G present examples of nonspecific fat on CMR. For 24 patients (6.6%), initial evaluation identified the presence of an epsilon wave, which was not corroborated for any of these patients upon second opinion evaluation of

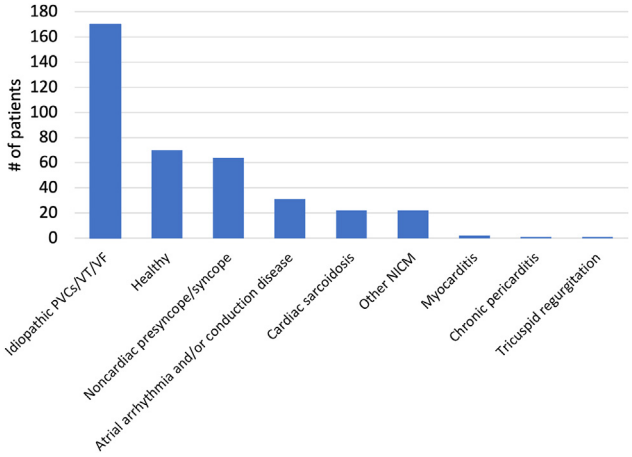

Figure 2 Final diagnoses of ruled-out patients (n = 365). NICM = nonischemic cardiomyopathy; PVC = premature ventricular contraction; VF = ventricular fibrillation; VT = ventricular tachycardia.

Table 3 Contributors to false suspicion or misdiagnosis (n = 365)

Pitfall	Value
False-positive RV wall motion abnormality on CMR	121 (33.2)
Missed pericardial tether	26 (7.1)
Missed pectus excavatum	21 (5.8)
Missed arrhythmia/bundle branch artifact	12 (3.3)
Benign fat on CMR	44 (12.1)
Athlete's heart/nonspecific RV dilation without wall motion abnormality	34 (9.3)
False-positive epsilon wave	24 (6.6)
Nonspecific RV wall thinning on CMR	13 (3.6)
Likely misdiagnosed family member	8 (2.2)

Values are presented by n (%).
CMR = cardiac magnetic resonance imaging; RV = right ventricular.

their ECG or of new ECGs performed at our center. Figure 4 shows a representative example of a mistaken epsilon wave.

In ruled-out patients, the 2 most common testing modalities that received second opinion interpretations were CMR and genetic testing. Table 4 compares the initial and second opinion interpretations for 3 important parts of ARVC workup: whether CMR met the 2010 TFC, whether RV WMAs were present on CMR, and how genetic variants were graded (benign/likely benign, variant of uncertain significance [VUS], or pathogenic/likely pathogenic). Cohen's κ test was used to determine the degree of agreement between the initial and second opinion interpretations. As shown in Table 4, there was only "slight agreement" in scoring of CMR via 2010 TFC and in calling the presence of RV WMAs in these patients (Cohen's κ values of 0.11 and 0.03, respectively). Note that the totals for these 2 categories are not the same since some outside test interpretations remarked on WMAs but not TFC (and vice versa). The interrater reliability of genetic testing was higher, falling in the "moderate agreement" range with a Cohen's κ value of 0.57. The largest source of disagreement in genetic testing occurred on VUS. Of the 56 variants considered VUS at the initial evaluation, 12 were reclassified as benign/likely benign, and 1 was reclassified as pathogenic/likely pathogenic upon reevaluation.

Discussion

In this single-center cohort study of 726 patients referred for ARVC at a tertiary expert center, there are 4 major findings. First, false suspicion or misdiagnosis of ARVC is common, occurring in the majority of the patients referred to our center for ARVC. Second, inappropriate ICD implantation or recommendation occurred in 14.5% of these patients. Third, the most common final diagnosis in these patients was idiopathic PVCs/VT/VF. Lastly, the most frequent contributor to misdiagnosis or false suspicion of ARVC in these patients was a misinterpretation of CMR findings.

Of the patients referred to our center for ARVC, 50.3% were ultimately determined not to have the disease. The

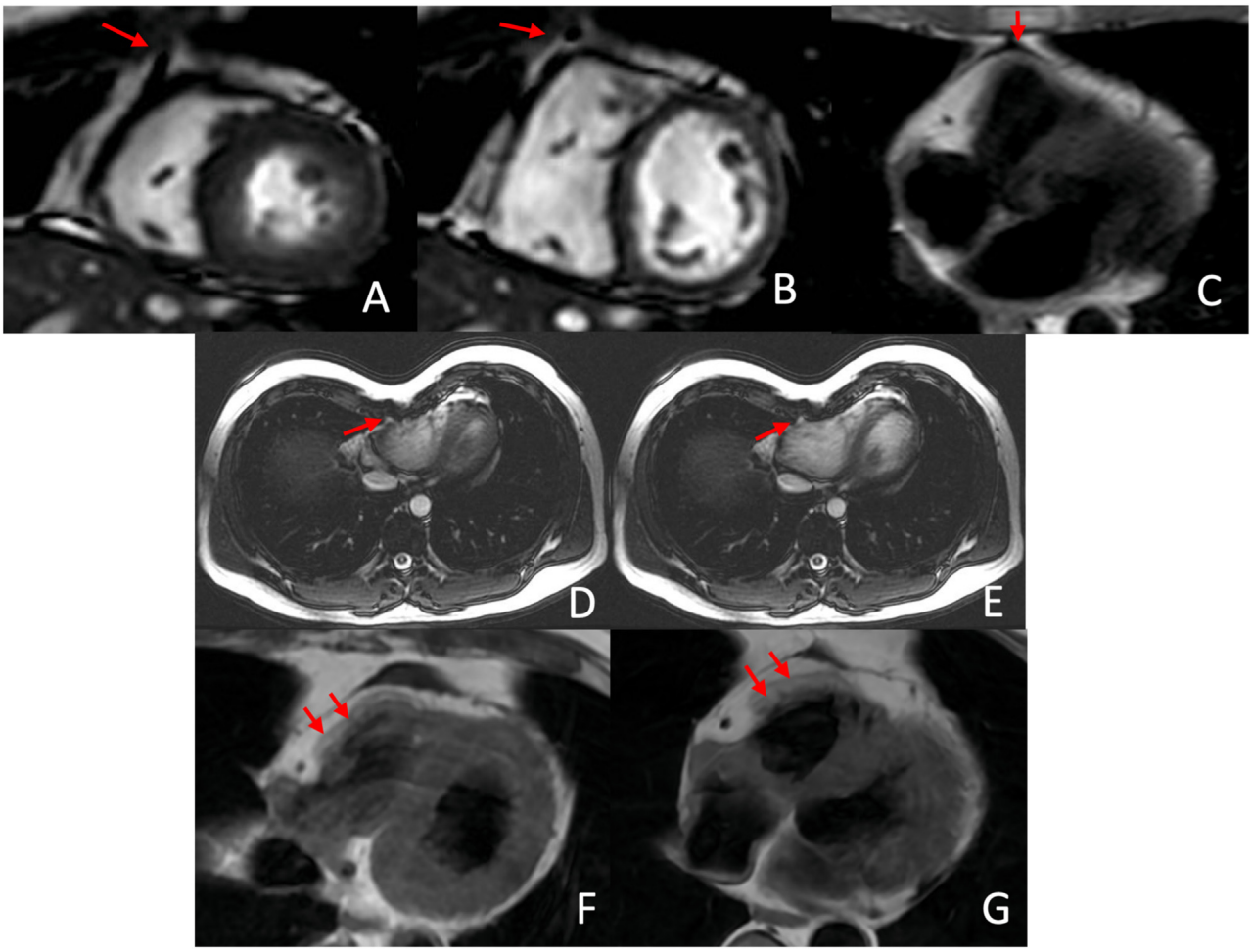

Figure 3 Representative examples of common CMR pitfalls. **A–C:** Pericardial tether in a 41-year-old woman. Outside report: "Dyskinetic RV free wall in the basal and middle segment of the heart, compatible with ARVC." Second opinion: "Pericardial tether, a benign anatomic variant that can make the RV appear dyskinetic." Panels A and B show short-axis views; the *red arrows* indicate the tether in systole and diastole, respectively. Panel C shows the tether on an axial dark blood image. **D and E:** Pectus excavatum in a 21-year-old woman. Outside report: "RV dyskinesis and depressed function, meeting 1 major criterion for ARVC." Second opinion: "Pectus excavatum deformity. Mildly enlarged and mildly hypokinetic RV with no other abnormalities." Panels D and E show an axial view in systole and diastole, respectively; the *red arrows* indicate the area of apparent dyskinesis. **F and G:** Benign fat in a 61-year-old woman that prompted ARVC referral. Panels E and F show benign fat infiltration in the RV free wall on axial dark blood images; the *red arrows* indicate the area of interest. ARVC = arrhythmogenic right ventricular cardiomyopathy; CMR = cardiac magnetic resonance imaging; RV = right ventricular.

misdiagnosis of ARVC was previously highlighted by Bomma et al[13] in 2004, in which 65 of 89 patients (73%) referred for ARVC were determined to be misdiagnosed. Our study, which adds a significantly larger cohort of 726 patients, continues to show a high rate of misdiagnosis/false suspicion, although lower than that in Bomma et al. Notably, an important difference in our study is that all patients in this cohort were evaluated after the introduction of the revised 2010 TFC. This lower rate of misdiagnosis may be related to the introduction of the 2010 TFC, but our study is not powered to make this comparison.

As shown in this cohort, false suspicion or true misdiagnosis has a significant effect on patient management. By the time of evaluation at our center, 14.5% of the subsequently ruled-out patients had either received inappropriate ICD implantations or recommendations. In addition to inappropriate interventions, patients may bear an opportunity cost to misdiagnosis or false suspicion since they may be treated inadequately for their true disease. For example, 6.0% of the ruled-out patients were ultimately diagnosed with cardiac sarcoidosis, which, unlike ARVC, would necessitate treatment with immunosuppression. Additionally, those patients require the use of a different algorithm for arrhythmic risk stratification and benefit from different lifestyle changes. Misdiagnosis also has implications for family members, since they are in turn recommended to undergo screening, which, in addition to financial and time costs, can also lead to their own misdiagnosis. Indeed, 8 patients in this cohort underwent initial evaluation owing to a family member's misdiagnosis (as determined by our center's review of their family member's medical records).

By a large margin, the most common diagnosis in ruled-out patients was idiopathic PVCs/VT/VF (46.6%). A typical scenario involved a patient who presented with such an

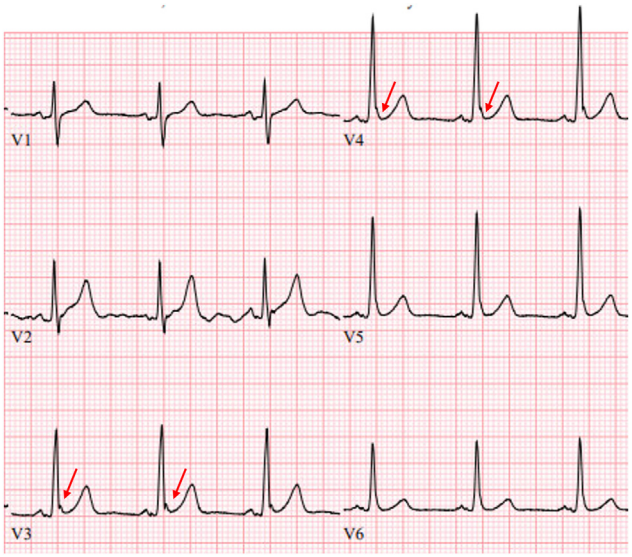

Figure 4 Representative example of a false-positive epsilon wave in a 54-year-old man. Outside interpretation: "Epsilon wave noted in leads V_3 and V_4." Second opinion interpretation: "Early repolarization." The *red arrows* indicate the mistaken epsilon wave.

arrhythmia and then underwent further testing that was misinterpreted as being consistent with ARVC. This finding is interesting because when discussing misdiagnosis, a focus is often placed on "ARVC mimics," such as cardiac sarcoidosis, that may closely resemble ARVC and even fulfill the 2010 TFC (as shown in 4 patients in our study).[14–16] However, our cohort suggests that while an ARVC mimic like cardiac sarcoidosis may be misdiagnosed as ARVC, a much more frequent cause of misdiagnosis includes more common conditions (such as idiopathic arrhythmias) that less closely resemble ARVC but are misdiagnosed owing to testing misinterpretation.

Table 4 Interrater reliability of test interpretation

Test	Characteristic	Outside interpretation	Second opinion interpretation	Interrater reliability
CMR – TFC	Major criterion	67	12	0.11
	Minor criterion	43	7	
	No criterion	152	243	
	Total	262		
CMR – WMA	RV WMA present	145	40	0.03
	RV WMA absent	118	223	
	Total	263		
Genetic test	Benign/likely benign	0	12	0.57
	VUS	56	43	
	Pathogenic/ likely pathogenic	12	13	
	Total	68		

Interrater reliability was calculated using Cohen's κ. Interrater agreement is graded as follows: 0 = none; 0.01–0.20 = slight; 0.21–0.40 = fair; 0.41–0.60 = moderate; 0.61–0.80 = substantial; 0.81–0.99 = near perfect; 1 = perfect.

CMR = cardiac magnetic resonance imaging; RV = right ventricular; TFC = Task Force Criteria; VUS = variant of uncertain significance; WMA = wall motion abnormality.

Our study showed that misinterpretation of CMR, rather than genetic testing, plays the largest role in misdiagnosis or false suspicion of ARVC. Previous studies have also described CMR as a contributor to misdiagnosis.[10,13,17,18] Our study confirms and expands these findings in a large cohort of patients and shows that these issues have persisted despite the introduction of specific, quantifiable CMR metrics in the revised 2010 TFC. Our study reveals 2 major types of errors in the interpretation of CMR. The first type of error involves mistaking an RV WMA owing to the presence of a confounding factor, such as pericardial tether, pectus excavatum, or arrhythmia/conduction artifact. This finding is consistent with those of Quarta et al[18] and highlights the importance of increased awareness of these artifacts to prevent misinterpretation. The second type of error involves diagnosing ARVC using CMR features that are not included in the 2010 TFC. For example, ARVC was frequently suspected or diagnosed on the basis of nonspecific fat, RV dilation/athlete's heart in the absence of an RV WMA, and RV wall thinning. Although fibrofatty myocardial infiltration, RV wall thinning, and RV dilation can be seen in ARVC, these CMR features were not considered reliable enough to be included in the 2010 TFC. This pattern of errors highlights the importance of using quantitative 2010 TFC when interpreting CMR findings rather than using a general gestalt for imaging interpretation. Overall, these findings suggest that providers should be cautious to diagnose patients primarily on the basis of CMR findings and that, when possible, review of CMR images by centers with experience in ARVC may be beneficial in most cases. In contrast to CMR, second opinion on genetic testing results did not significantly affect clinical diagnosis, as most reinterpretations involved reclassifying "VUS" results as "benign/likely benign."

Notably, another important source of diagnostic error in our cohort was the epsilon wave, which currently constitutes a major criterion in the revised 2010 TFC. In this study, a false-positive epsilon wave was seen in 6.6% of the ruled-out patients. This finding supports a prior study that also highlighted the high interobserver variability in the detection of the epsilon wave.[19] Given this poor reliability, reliance on epsilon waves for the diagnosis of ARVC should be avoided, especially since they are typically seen only in patients with advanced disease (in which case patients likely meet TFC through other criteria).

Limitations

This study is limited as a result of being an analysis from a single institution. Additionally, certain data, such as outside interpretation of RV WMAs on CMR, were not available for every patient.

Conclusion

False suspicion or misdiagnosis was found in 50.3% of patients referred to our center, leading to inappropriate ICD

implantation or recommendation in 14.5% of these patients. The most common diagnoses in these patients were idiopathic ventricular arrhythmias, and the most common contributor to false suspicion or misdiagnosis involved a misinterpretation of CMR findings.

Acknowledgments

We are grateful to patients with arrhythmogenic right ventricular cardiomyopathy and families who have made this work possible.

Funding Sources: The Johns Hopkins ARVD/C Program is supported by the Leonie-Wild Foundation; the Leyla Erkan Family Fund for ARVD Research; the Hugh Calkins, Marvin H. Weiner and Jacqueline J. Bernstein Cardiac Arrhythmia Center; the Dr Francis P Chiaramonte Private Foundation; the Dr. Satish, Rupal, and Robin Shah ARVD Fund at Johns Hopkins; the Bogle Foundation; the Campanella family; the Patrick J. Harrison family; the Peter French Memorial Foundation; and the Wilmerding endowment.

Disclosures: Ms Tichnell is a consultant for StrideBio. Ms Murray is a consultant for My Gene Counsel. Dr Zimmerman has been a consultant for Siemens Healthcare and receives research support from Bayer Healthcare. Dr James has been a consultant for Pfizer and Lexeo Therapeutics and an unpaid consultant for StrideBio. She receives research support from StrideBio and Lexeo Therapeutics; Ms Tichnell and Dr Gasperetti receive salary support on this grant. Dr Gasperetti served on an advisory board for Lexeo Therapeutics. Dr Calkins is a consultant for Medtronic, Biosense Webster, Pfizer, StrideBio, Rocket, and Abbott. He receives research support from Boston Scientific; Ms Tichnell and Dr James receive salary support from this grant. Dr Calkins receives research support from Medtronic, Biosense Webster, Farapulse, and Adagio. The rest of the authors report no conflicts of interest.

References

1. Groeneweg JA, Bhonsale A, James CA, et al. Clinical presentation, long-term follow-up, and outcomes of 1001 arrhythmogenic right ventricular dysplasia/cardiomyopathy patients and family members. Circ Cardiovasc Genet 2015;8:437–446.
2. Basso C, Corrado D, Marcus FI, Nava A, Thiene G. Arrhythmogenic right ventricular cardiomyopathy. Lancet 2009;373:1289–1300.
3. James CA, Jongbloed JDH, Hershberger RE, et al. International evidence based reappraisal of genes associated with arrhythmogenic right ventricular cardiomyopathy using the clinical genome resource framework. Circ Genom Precis Med 2021;14:e003273.
4. Quarta G, Muir A, Pantazis A, et al. Familial evaluation in arrhythmogenic right ventricular cardiomyopathy: impact of genetics and revised Task Force Criteria. Circulation 2011;123:2701–2709.
5. Cox MG, van der Zwaag PA, van der Werf C, et al. Arrhythmogenic right ventricular dysplasia/cardiomyopathy: pathogenic desmosome mutations in index-patients predict outcome of family screening: Dutch arrhythmogenic right ventricular dysplasia/cardiomyopathy genotype-phenotype follow-up study. Circulation 2011;123:2690–2700.
6. van Lint FHM, Murray B, Tichnell C, et al. Arrhythmogenic right ventricular cardiomyopathy-associated desmosomal variants are rarely de novo. Circ Genom Precis Med 2019;12:e002467.
7. McKenna WJ, Thiene G, Nava A, et al. Task Force of the Working Group Myocardial and Pericardial Disease of the European Society of Cardiology and of the Scientific Council on Cardiomyopathies of the International Society and Federation of Cardiology. Diagnosis of arrhythmogenic right ventricular dysplasia/cardiomyopathy. Br Heart J 1994;71:215–218.
8. Marcus FI, McKenna WJ, Sherrill D, et al. Diagnosis of arrhythmogenic right ventricular cardiomyopathy/dysplasia: proposed modification of the Task Force Criteria. Circulation 2010;121:1533–1541.
9. Corrado D, van Tintelen PJ, McKenna WJ, et al. Arrhythmogenic right ventricular cardiomyopathy: evaluation of the current diagnostic criteria and differential diagnosis. Eur Heart J 2020;41:1414–1429.
10. Sharma A, Assis F, James CA, et al. Misdiagnosis of ARVC leading to inappropriate ICD implant and subsequent ICD removal—lessons learned. J Cardiovasc Electrophysiol 2019;30:2020–2026.
11. Rhodes AC, Murray B, Tichnell C, James CA, Calkins H, Sears SF. Quality of life metrics in arrhythmogenic right ventricular cardiomyopathy patients: the impact of age, shock and sex. Int J Cardiol 2017;248:216–220.
12. Richards S, Aziz N, Bale S, et al. Standards and guidelines for the interpretation of sequence variants: a joint consensus recommendation of the American College of Medical Genetics and Genomics and the Association for Molecular Pathology. Genet Med 2015;17:405–424.
13. Bomma C, Rutberg J, Tandri H, et al. Misdiagnosis of arrhythmogenic right ventricular dysplasia/cardiomyopathy. J Cardiovasc Electrophysiol 2004;15:300–306.
14. Gasperetti A, Rossi VA, Chiodini A, et al. Differentiating hereditary arrhythmogenic right ventricular cardiomyopathy from cardiac sarcoidosis fulfilling 2010 ARVC Task Force Criteria. Heart Rhythm 2021;18:231–238.
15. Dechering DG, Kochhauser S, Wasmer K, et al. Electrophysiological characteristics of ventricular tachyarrhythmias in cardiac sarcoidosis versus arrhythmogenic right ventricular cardiomyopathy. Heart Rhythm 2013;10:158–164.
16. Philips B, Madhavan S, James CA, et al. Arrhythmogenic right ventricular dysplasia/cardiomyopathy and cardiac sarcoidosis: distinguishing features when the diagnosis is unclear. Circ Arrhythm Electrophysiol 2014;7:230–236.
17. Rastegar N, Burt JR, Corona-Villalobos CP, et al. Cardiac MR findings and potential diagnostic pitfalls in patients evaluated for arrhythmogenic right ventricular cardiomyopathy. Radiographics 2014;34:1553–1570.
18. Quarta G, Husain SI, Flett AS, et al. Arrhythmogenic right ventricular cardiomyopathy mimics: role of cardiovascular magnetic resonance. J Cardiovasc Magn Reson 2013;15:16.
19. Platonov PG, Calkins H, Hauer RN, et al. High interobserver variability in the assessment of epsilon waves: implications for diagnosis of arrhythmogenic right ventricular cardiomyopathy/dysplasia. Heart Rhythm 2016;13:208–216.